

Management of Crush Injury with Homoeopathic Medicine –A Case Report

Dr. Mohammad Rafi¹, Dr. Arvind Kumar Singh², Dr. Bhanu Pratap Singh³

¹b.H.M.S, M.D. (Homoeopathy), Associate Professor And Hod, Human Anatomy

²b.H.M.S, Associate Professor, Homoeopathic Materia Medica

³b.H.M.S, M.D. (Homoeopathy), Professor And Hod, Homoeopathic Materia Medica

¹drbhanusingh1987@gmail.com , ²dr.arvindsingh13@gmail.com , ³rafi078@gmail.com

ABSTRACT:

Crush injury occurs when blunt trauma causes prolonged or sudden compression of any body part or whole body by any heavy object. This results bleeding, fractures, muscle damage, nerve damage necrosis and systemic effects. Crush injury refers to Crush syndrome: a severe systemic condition, that develops after prolonged pressure on muscles from crush injuries, causing muscle cells to break down and release potassium, myoglobin like harmful substances in bloodstream, that causes electrolyte imbalance that leads to shock and acute renal failure. In this case of crush injury, a 25 year old male came to my OPD, his middle finger of right hand caught in the door, severe pain and blackish discoloration were present in his finger. He applied su-mag ointment on the finger suggested by some doctor. Homoeopathy reduces the need for surgical intervention. This case shows the usefulness of homoeopathic medicine in acute injury cases. A case of Crush injury is treated according to the homoeopathic approach, guidelines with individualised Homoeopathic medicine Arnica Montana. The Crush injury treated completely without any adverse events. The outcome was analysed along with the photographs.

Key words: - Crush injury, Homoeopathy, Homoeopathic medicine, Constitutional medicine, Miasmas.

1. INTRODUCTION:

Crush injury occurs when blunt trauma caused by prolonged or sudden compression of any body part or whole body by any heavy object. This results in bleeding, fractures, muscle damage, nerve damage, necrosis and systemic effects. Crush injury refers to Crush syndrome: a severe systemic condition, that develops after prolonged pressure on muscles from crush injuries, causing muscle cells to break down and release potassium, myoglobin like harmful substances in blood, that causes electrolyte imbalance that leads to shock and acute renal failure.

Role of homoeopathy in crush injury:

Arnica Montana is a known homoeopathic medicine for blunt injuries. It promotes the regeneration of healthy tissues and removal of dead cells. It has marked effect on blood, it helps in dissolving the clots of blood and helps in proper and rapid healing.

It recommend when injury is caused by falls, blows, contusions. Limbs and body ache as if beaten, bed feels so hard. Relaxed blood vessels, and removes the black and blue spots.

CASE PROFILE:

A male patient aged 25 years, came to my OPD with complaints of Painful swelling and blackish bluish discolouration on his middle finger of right hand since last 3 days due to getting caught in the door. Additionally, he reported pain all over the body at night. The pain redness and swelling were progressively increasing, causing difficulty in doing routine work.

History of presenting complaints:

The patient name xyz age 25 year old male was suffering from severe pain in right hand's middle finger. The finger was caught in door due to this crush injury, he feel pain with marked blackish bluish discoloration at the same time he noticed the body ache at night. Over the time pain and swelling increased. At that affected area, black and bluish discolouration started developing and he felt tightness and heaviness in his finger.

Location : Right hand's middle finger.

Sensation : Sensitive to touch, throbbing type of pain.

Modalities : Aggravation by motion and lying down.

Treatment history:

He had previously used some topical creams and allopathic treatment.

Family History : Father was tubercular. And mother was normal

Physical General : Painful swelling and blackish bluish discolouration, restless, pain was less when hanging the hand and worsened when walking and standing.

Appetite : Loss of appetite.

Thirst : normal

Stool : normal

Sleep : disturbed

Thermal reaction : chilly patient

Mental general : confused , restless, do not want to talk to anyone.

Examination :

General examination

Pulse : 84/min

BP : 120/84 mmhg

Temperature : 97°F

Local examination

The affected area was hot and tender, surrounded by blackish bluish discolouration on nails and affected finger of right hand. Tenderness was present, and the finger felt heavy with throbbing sensation, causing pain during movement of the hand.

Clinical diagnosis : Crush injury of middle finger.

Selection Of Medicine And Medicine Prescribed:-

On the basis of totality in Pocket Manual Of William Boericke Materia Medica And Repertory Arnica Montana was the remedy.

Arnica Montana 200 single dose.

Calendula Officinalis Q for topical application.

Placebo 200 BD.

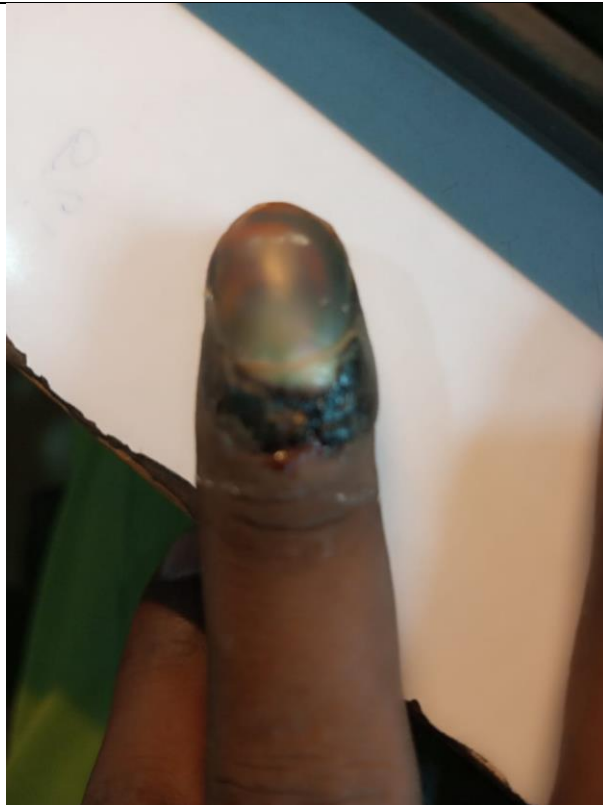
Table 1: Follow up details:

Date of	Presenting Complaints	Medicine with doses
10-02-2025 1 st visit	Painful Swelling with blackish discolouration present in right hand's middle finger. Throbbing pain with highly sensitive to touch. PIC-01	Arnica Montana 200 single dose in morning 3 doses and placebo bd given for 4 days Calendula Officinalis Q for topical application
16-02-2025 2 nd Visit	Pain, was reduced	Arnica Montana 200 was repeated stat in clinic. Placebo was given for next 3 days
19-02-2025 3 rd visit	Affected area became bluish and slight detachment of nail was present . Pain was not present.	Arnica Montana 200 single dose was given in clinic. Placebo was given for 11 days
29-02-	Affected finger became reddish nail was	Arnica Montana 200 single dose was given

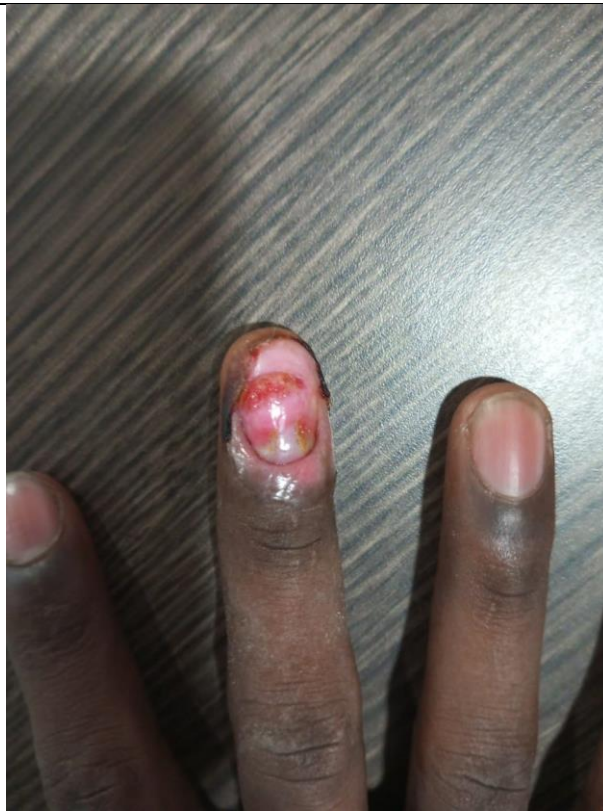2025 4 th Visit	detached. Swelling and pain was also reduced.	in clinic placebo given for 14 days
08-03- 2025 5 th Visit	The lesion was clearing with only slight discoloration of the skin present.	Placebo given for 15 days.
06-04- 2025 6 th Visit	Nail was detached no pain or swelling was present. Lesion was healthy.	Placebo given for 15 days.
12-11- 2025 7 th Visit	After 7 month patient came to OPD with completely healed finger with nail regrowth.	No further medicine was given.

Table 1: Follow up pictures

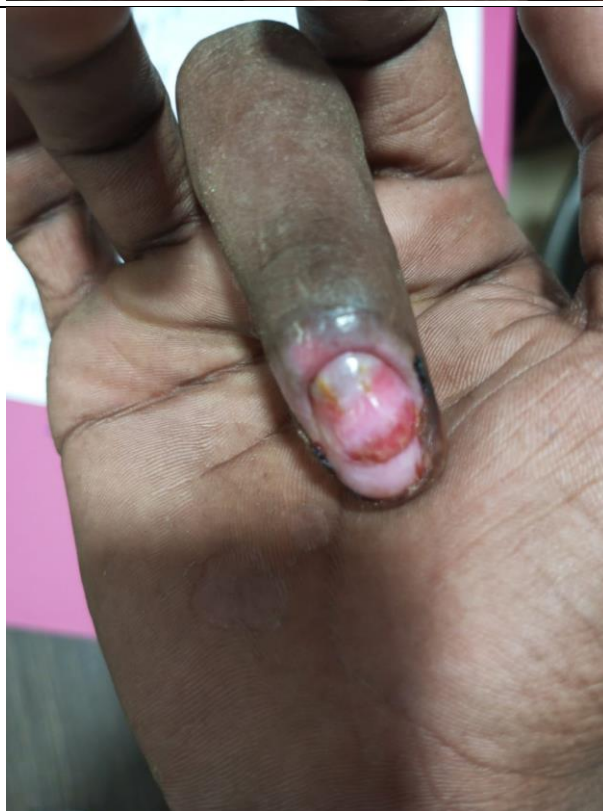1 st visit	
-----------------------	---

2nd visit3rd visit

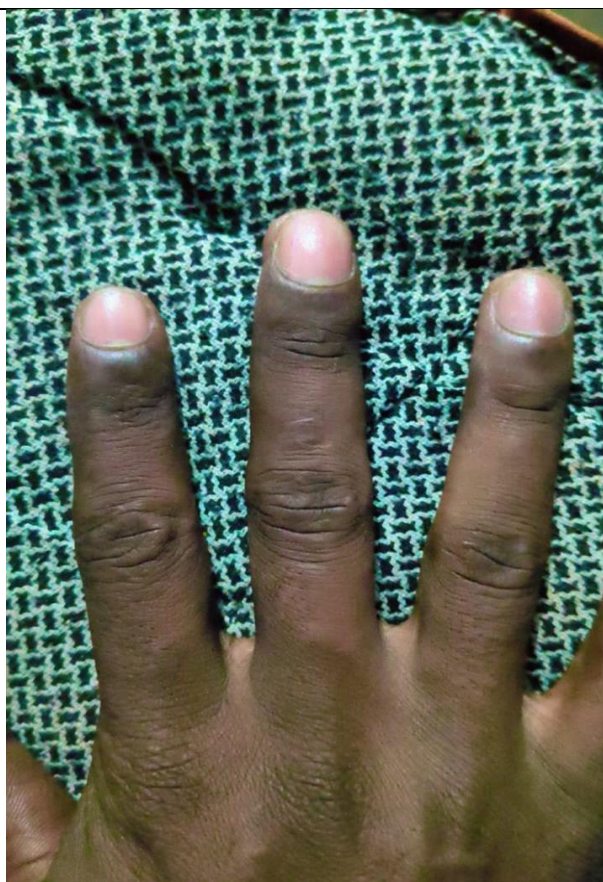4th visit



5th visit



Last visit



Result and discussion:

In homoeopathy we treat the patient (individual) not the disease by merely its name and diagnosis. Our approach to every individual case is to improve the vitality and immunity of the patient with our homoeopathic medicines, so that the patient can get back to normalcy, without any adverse and unwanted complication. This case presented with pain swelling and blackish bluish discolouration of middle finger due to crush injury by sudden closure of door. The patient was already under medication for the same and the doctors suggested minor surgical approach (removal of the nail and necrosed part). On his first visit the patient presented with pain, swelling and blackish bluish discolouration on middle finger of right hand with difficulty in his routine work. So Arnica Montana 200 was the first prescription on the basis of totality of symptom. On his subsequent visits, the potency was same and the swelling, pain and blackish discolouration reduced gradually (as shown in table 2). The patient came after 7 months, with completely healed finger and a new healthy nail.

Conclusion:

This case definitely confirms the efficacy of homoeopathy for managing such case of injury. As it is clearly evidence that in this condition doctor advised him for surgery. Whereas, on the proper and detailed history taking based on the Dr Hahnemann's homoeopathic principle, we could provide him relief from not only physical symptoms but also his mental anxiety.



Acknowledgments: - I acknowledge efforts of my wife Dr. Unaiza Siddiqui and at the same time, patient's family support and cooperation for regular follow-ups is commendable.

Conflict of interest: - none

Financial support: - none

Ethics statement: - Informed consent for publication of this report was taken from patient's family.

References

1. K Rajgopal Shenay, Anitha Shenay- Manipal manual of surgery
2. Bailey IS, Love WG. The Assessment Of Surgical Wounds And The Clinical Significance Of Infection. J Wound Care.1992;1(3):21`65-2170
3. Dr.Mr. Sachin E Kadam M.D.(Hom) ;2025 A Review Of Literature On Arnica Montana As A Polycrest Remedy With Homoeopathic Perspective,In Acute As Well As Chronic Cases. VOL32 NO 09 (2025)JPTCP(388-394)
4. World Health Organization (WHO). Wound And Wound Management Guidelines, Geneva WHO; 2022
5. William Boericke,MD, Pocket Manual Of Homoeopathic Materia Medica And Repertory, B. Jain publishers